



# Rectum lipoma incarcerated in the anus as a cause of abundant rectorrhagia

## Lipom rektuma inkarceriran u anusu kao uzrok obilne rektoragije

Katarina Erić\*, Marko Miladinov\*, Zoran Krivokapić\*†‡

\*University Clinical Center of Serbia, Clinic for Digestive Surgery, First Surgical Clinic, Belgrade, Serbia; †University of Belgrade, Faculty of Medicine, Belgrade, Serbia; ‡Serbian Academy of Sciences and Arts, Belgrade, Serbia

### Abstract

**Introduction.** Lipomas are slow-growing, benign tumors of mesenchymal origin. In most cases, they are incidental findings during endoscopic examinations. Lipomas in the gastrointestinal tract are rare entities with the lowest rate of occurrence in the rectum. They are mostly asymptomatic but can cause pain, intussusception, bleeding, volvulus, prolapse, and weight loss if larger than 4 cm. The aim of the presented case report was to demonstrate that abundant rectorrhagia can be caused by a rare entity such as rectal lipoma. **Case report.** We presented the case of a fifty-year-old male patient with a soft-structure prolapse through the anus accompanied by extensive bleeding. After repositioning, the structure was endoscopically removed. Histopathological analysis confirmed the presence of a lipoma. **Conclusion.** Rectorrhagia can be a clinical manifestation of this rare condition – incarcerated rectal lipoma – and should be considered in practice as a differential diagnosis in cases where the existence of more common conditions like hemorrhoidal disease and malignant tumors is excluded.

### Key words:

diagnosis, differential; gastrointestinal hemorrhage; hemostasis, endoscopic; histological techniques; lipoma; rectal neoplasms.

### Apstrakt

**Uvod.** Lipomi su spororastući, benigni tumori mezenhimalnog porekla. U većini slučajeva se njihovo prisustvo slučajno otkriva tokom endoskopskih ispitivanja. Lipomi u gastrointestinalnom traktu su retki i najređe su prisutni u rektumu. Uglavnom su asimptomatski, ali ukoliko su veći od 4 cm mogu uzrokovati bolove, intususcepciju, krvarenje, volvulus, prolaps i gubitak telesne mase. Cilj prikaza bio je da se pokaže da uzrok obilne rektoragije može biti i redak entitet kao što je lipom rektuma. **Prikaz bolesnika.** Prikazali smo slučaj 50-godišnjeg bolesnika sa prolapsom mekotkivne strukture kroz anus, praćenim obilnim krvarenjem. Nakon repozicije, struktura je endoskopski uklonjena. Histopatološkom analizom potvrđeno je prisustvo lipoma. **Zaključak.** Rektoragija može biti klinička manifestacija ovog retkog stanja – inkarceriranog lipoma rektuma – i trebalo bi da se razmatra u praksi kao diferencijalna dijagnoza u slučajevima kada je isključeno postojanje češćih uzroka rektoragije, kao što su hemoroidalna bolest i maligni tumor.

### Ključne reči:

dijagnoza, diferencijalna; krvarenje, gastrointestinalno; hemostaza, endoskopska; histološke tehnike; lipom; rektum, neoplazme.

### Introduction

Lipoma is a benign tumor of mesenchymal origin, produced by the proliferation of mature fat cells <sup>1</sup>. Lipoma in the colon was first described in 1757 by Bauer <sup>2</sup>. Lipomas are most frequently located in the right colon <sup>1</sup>. Rectal lipomas account for 5% of all lipomas in the gastrointestinal tract <sup>3</sup>. They are the third most prevalent tumors among all benign tumors

in the rectum, after hyperplastic polyps and adenomas <sup>4</sup>. In most cases, lipomas are incidental findings made during diagnostic procedures and surgical interventions. In rare cases, they can lead to clinical manifestations such as pain, intussusception, bleeding, volvulus, prolapse, and weight loss <sup>3</sup>, and extremely rarely to extensive bleeding. The aim of the presented case report is to demonstrate that abundant rectorrhagia can be caused by a rare entity such as rectal lipoma.

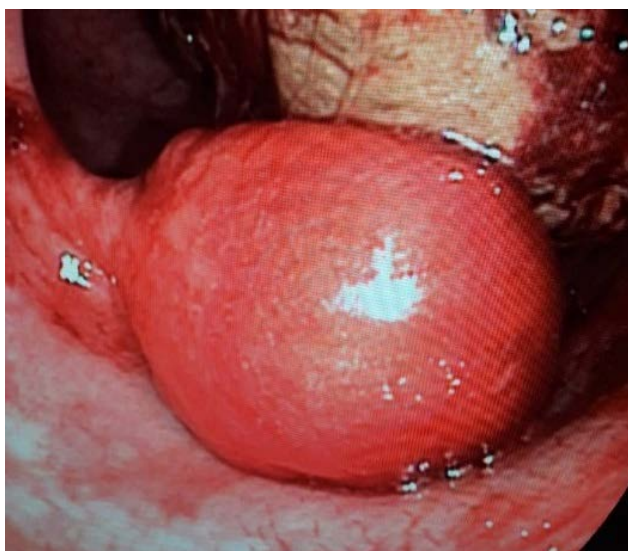
### Case report

We presented the case of a fifty-year-old patient who came to the Outpatient Clinic of the Digestive Surgery Clinic within the University Clinical Center of Serbia because of abundant hemorrhage from the perianal region. The patient was bleeding so profusely that blood was present on his trousers, underwear, and both thighs. Inspection of the perianal region revealed a prolapse of polypoid neoplastic formation, blood-saturated, with a soft consistency and eroded bleeding surface. The structure was examined and carefully manually repositioned into the anus. The first assumption was that the prolapsed formation was an incarcerated hemorrhoid since the patient had suffered from the hemorrhoidal disease for several years. Although he often suffered bleeding from hemorrhoids, the patient was treated conservatively and was never examined anoscopically. Differentially, both benign and malignant rectal polyps and rectal mucosal prolapse were considered. After the repositioning and the anoproctoscopy, a flexible rectoscopy was performed on the unprepared intestine, and the described polypoid tumor on the peduncle on the right lateral wall of the

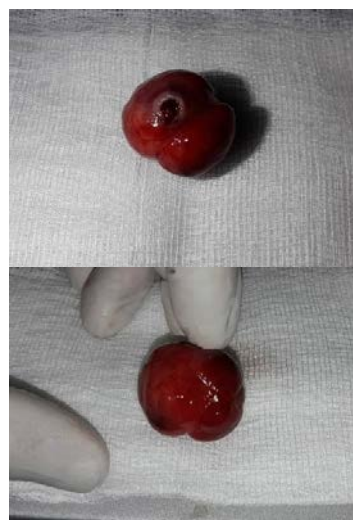distal rectum was verified, some 3.5 cm from the dentate line of the anus (Figure 1). Incarceration was probably caused by tumor peduncle torsion and reflex anal sphincter spasm. The tumor was electroresected entirely after infiltrating the peduncle with a solution of adrenaline and sent for histopathological examination. Instant hemostasis was achieved by clipping the tumor base residue. The patient tolerated the intervention well and was released shortly after the procedure. The lesion, 28 × 25 × 24 mm in size (Figure 2), was submitted for histopathological examination (Figures 3 and 4), which confirmed the finding of lipoma.

### Discussion

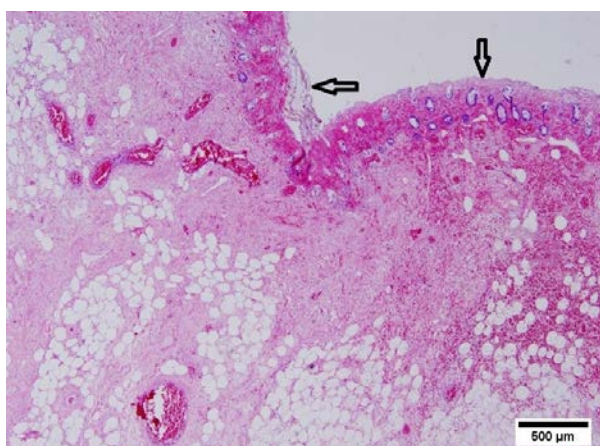
Lipomas are rare, most commonly solitary tumors in the gastrointestinal tract, with an overall incidence ranging between 0.2% and 4.4%<sup>5</sup>. They occur equally in both genders, most frequently in the sixth decade of life<sup>6</sup>. The most common location of lipomas in the gastrointestinal tract is the right colon<sup>6</sup>, and very rarely in the rectum – in about 3.9% of all reported cases<sup>7</sup>. Lipomas are predominantly presented as sessile



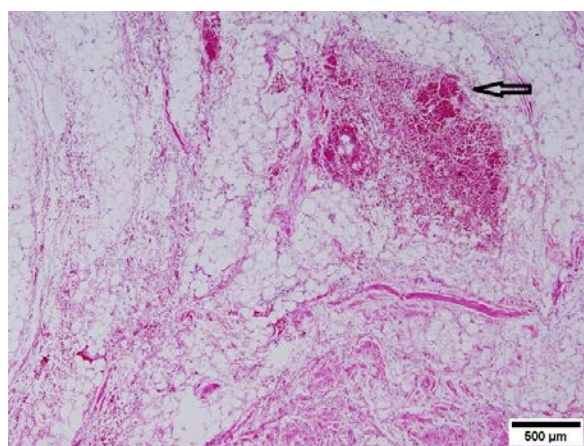
**Fig. 1 – Colonoscopic presentation of a tumor in the distal rectum.**



**Fig. 2 – Macroscopic presentation of a sessile polypoid tumor, with a base strongly saturated with blood.**



**Fig. 3 – Histological presentation of submucosal rectum lipoma with eroded mucosa accompanied by bleeding foci (arrows) (hematoxylin and eosin, ×40).**



**Fig. 4 – Histological presentation of submucosal rectum lipoma with intralipomal bleeding (arrow) (hematoxylin and eosin, ×40).**

or pedunculated pseudopolypoid tumors. Macroscopically, sections reveal a yellow, clearly defined structure. In 90% of cases, they are submucosal, and the remaining 10% are subserous and intramuscular<sup>8</sup>. Lipomas are generally asymptomatic, whilst those larger than 4 cm always manifest clinically<sup>6</sup>. The clinical manifestations of colon and rectum lipomas are abdominal colic, rectal bleeding, peristalsis disorder, colonic-colon intussusception, weight loss, sigmoid colon volvulus, and spontaneous lipoma expulsion<sup>6</sup>. In the case presented here, rectal lipoma was manifested by extensive rectal bleeding, which was cited by Crocetti et al.<sup>6</sup> as a complication in 46% of patients. Bleeding can be acute and chronic and can cause anemia when it is occult. The likelihood of a lipoma causing rectal bleeding is thought to correlate directly to tumor size. In lipomas larger than 4 cm, rectal bleeding has been reported in 10% of cases<sup>9</sup>. In the present case, the patient had profuse secondary bleeding even though the maximum tumor size was less than 3 cm. Bleeding was caused by incarceration in the anus, necrosis within the tumor, and mucosal erosion. Lipoma prolapse through the anus is rare<sup>10</sup> and has been described in several papers. In all cases, including ours, rectal prolapse or prolapsed hemorrhoids were first contemplated<sup>11,12</sup>. Spontaneous lipoma expulsion is a very rare clinical manifestation. It occurs in large pedunculated lipomas. These entities produce a twist of the peduncle and its necrosis leading to tumor autoamputation and its spontaneous expulsion through the anus<sup>9</sup>. Intussusception, in addition to rectal bleeding, is the rectal lipoma's most important urgent complication<sup>13</sup>. In adult patients, the incidence of intussusception is about 1%<sup>4</sup>. Preoperative diagnosis of lipoma can be made based on the radiographic findings – computed tomography and magnetic resonance imaging – and during colonoscopy. Three

signs help diagnose lipomas during colonoscopy: "tenting sign" (grasping the overlying mucous), "cushion sign", and "naked fat sign" (fat tissue extrusion after colon mucosal biopsy)<sup>6</sup>. During these diagnostic procedures, it is sometimes difficult to distinguish lipoma from polypoid cancers. In 2016, Chakrabarti and Goenka<sup>3</sup> described the case of confocal laser endomicroscopy first used for diagnostic purposes. It is a novel method used to diagnose gastrointestinal lesions, predominantly in polypoid colorectal lesions, and to provide tissue diagnosis at both cellular and subcellular levels. Regardless of the state-of-the-art technologies used in diagnostic medicine, histopathology is still the gold standard in diagnosis<sup>8</sup>. The surgical approach depends solely on the size of the tumor, its location, accompanying complications, and suspected malignancy<sup>9</sup>. Lipomas smaller than 2 cm in size should be removed endoscopically<sup>14</sup>. For large lipomas, surgical resection in the form of colotomy or segmental colon resection is recommended<sup>6</sup>. Laparoscopic colon and rectum resection is the gold standard in removing giant lipomas because of shorter hospitalization, faster recovery, and lower risk of complications<sup>15</sup>. Rectal lipomas that prolapse through the anus are surgically removed by transanal resection or local excision<sup>10,11</sup>. The presented patient underwent local endoscopic excision of the lipoma that prolapsed through the anus.

### Conclusion

Rectal lipoma is a rare entity. Bleeding from the rectum can be a clinical manifestation of incarcerated rectal lipoma, and it should be considered in practice as a differential diagnosis concerning the presence of hemorrhoidal disease and malignant tumors.

### R E F E R E N C E S

1. *Krishnan P, Adlekha S, Chadha T, Babu A.* Rectal lipoma associated with genital prolapse. *Ann Med Health Sci Res* 2013; 3(Suppl 1): S18–20.
2. *Bagherzade G, Etemad O.* Recto-sigmoid lipoma: a case report and review of the literature. *J Coloproctol (Rio J)* 2016; 37(1): 50–4.
3. *Chakrabarti A, Goenka MK.* Submucosal lipoma of the rectum presenting with rectal prolapse and appearing as an adenomatous polyp on confocal laser endomicroscopy: a case report and review of literature. *Gastroenterol Hepatol Open Access* 2016; 5(1): 00126.
4. *Wei R, Xu W, Xiao Y, Yeng F, Mao S.* Laparoscopic segmental resection of the rectum for upper rectal intussusception caused by a giant rectal lipoma. *Medicine* 2018; 97(39): e1227.
5. *Dultz LA, Ullery BW, Sun HH, Huston TL, Eachempati SR, Barie PS, et al.* Ileocecal valve lipoma with refractory hemorrhage. *JLS.* 2009; 13: 80–83. (English)
6. *Crocetti D, Sapienza P, Sterpetti AV, Paliotta A, De Gori A, Pedulla G et al.* Surgery for symptomatic colon lipoma: A systematic review of the literature. *Anticancer Res.* 2014; 34(11): 6271–6.
7. *Manickavasagam K, Chandramohan S, Lakshmi J, Vairavan K, Madhusudhanan J.* Intussuscepting rectal lipoma: A case report and review of literature. *Int J Gastroenterol* 2012; 11(1): doi: 10.5580/2bd3.
8. *Yaman I, Derici H, Demirpolat G.* Giant colon lipoma. *Ulus Cerrahi Derg.* 2015; 31(2): 76–81.
9. *Kouritas VK, Baloyiannis I, Koukoulis G, Mamaloudis I, Zacharoulis D, Eftimiou M.* Spontaneous expulsion from rectum: a rare presentation of intestinal lipomas. *World J Emerg Surg* 2011; 6: 19.
10. *Martellucci J, Civitelli S, Tanzini G.* Transanal resection of rectal lipoma mimicking rectal prolapse: description of a case and review of the literature. *ISRN Surg* 2011; 2011: 170285.
11. *Kose E, Cipe G, Demirkan S, Oğuz S.* Giant colonic lipoma with prolapse through the rectum treated by external local excision: A case report. *Oncol Lett* 2014; 8(3): 1377–9.
12. *Ghanem OM, Slater J, Singh P, Heitmiller RF, DiRocco JD.* Pedunculated colonic lipoma prolapsing through the anus. *World J Clin Cases* 2015; 3(5): 457–61.
13. *Shobeiryan F, Mebrnabad M, Soleimantabar H.* Rectal lipoma as a lead point for colo-colonic intussusception. *Raiol Case Rep* 2018; 13(2): 431–3.
14. *Fernandes J, Libanio D, Giestas S, Araújo T, Martínez-Ares D, Certo M, et al.* Giant symptomatic rectal lipoma resected by endoscopic submucosal dissection. *Endoscopy.* 2018; 50: E63–E64.
15. *Arora R, Kumar A, Bansal V.* Giant rectal lipoma. *Abdom Imaging* 2011; 36(5): 545–7.

Received on June 27, 2020

Revised on March 21, 2021

Accepted on March 22, 2021

Online First March 2021